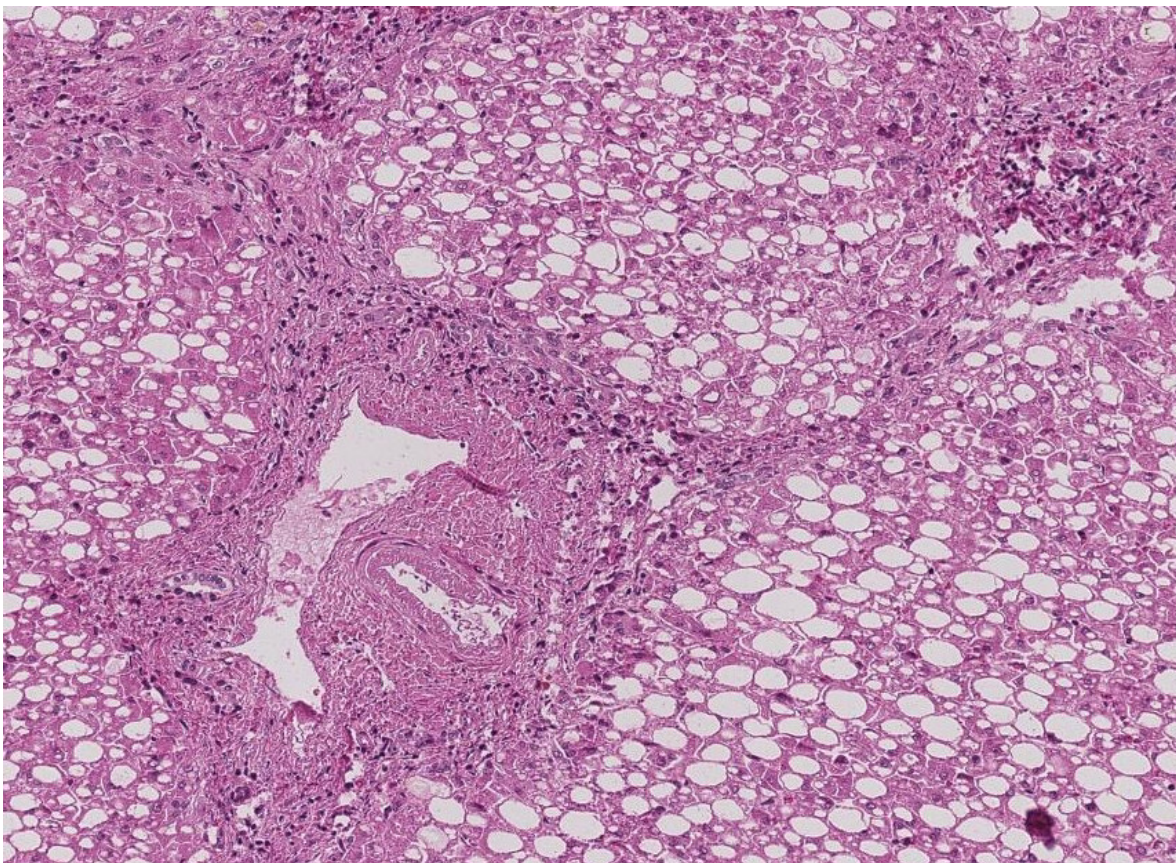
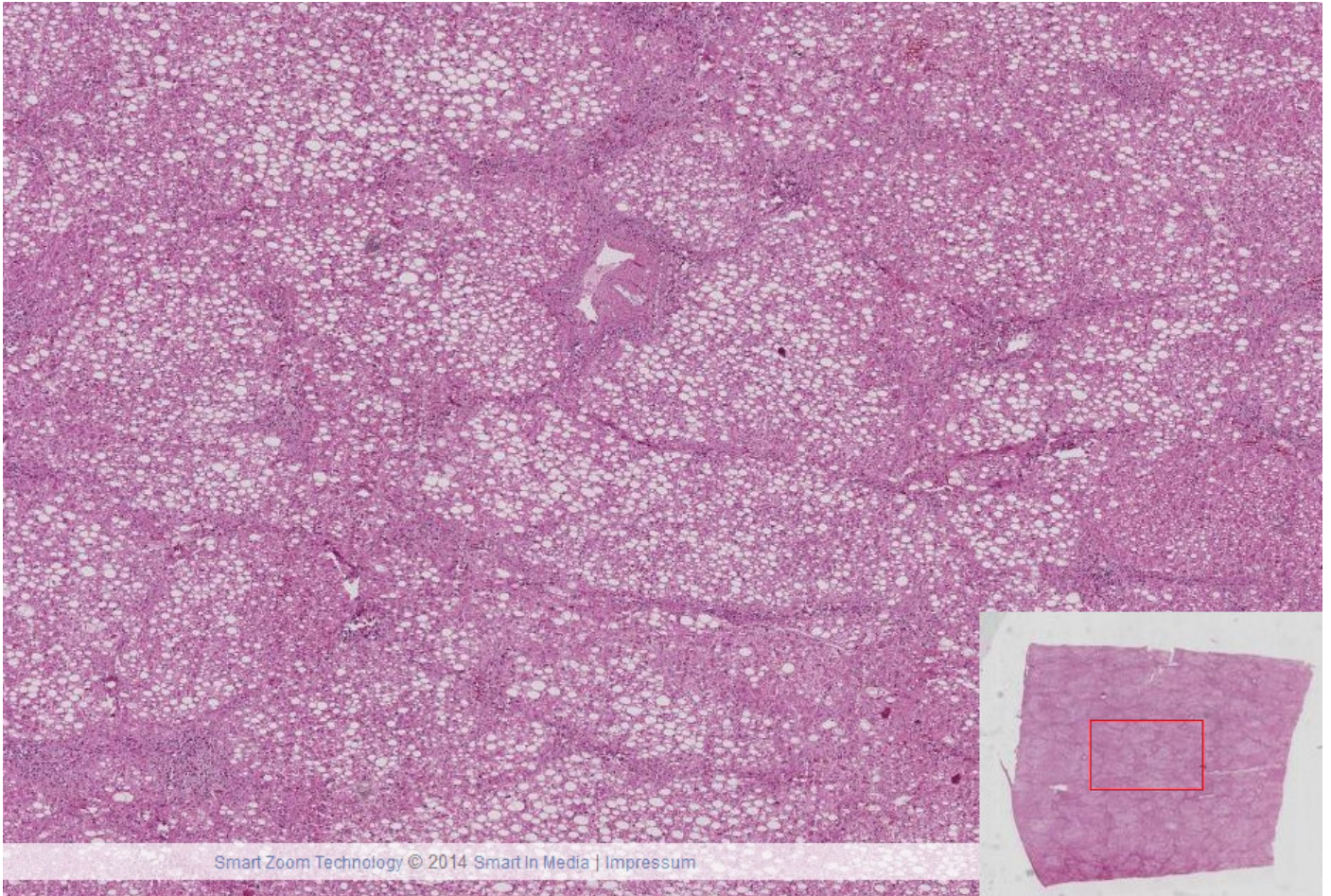
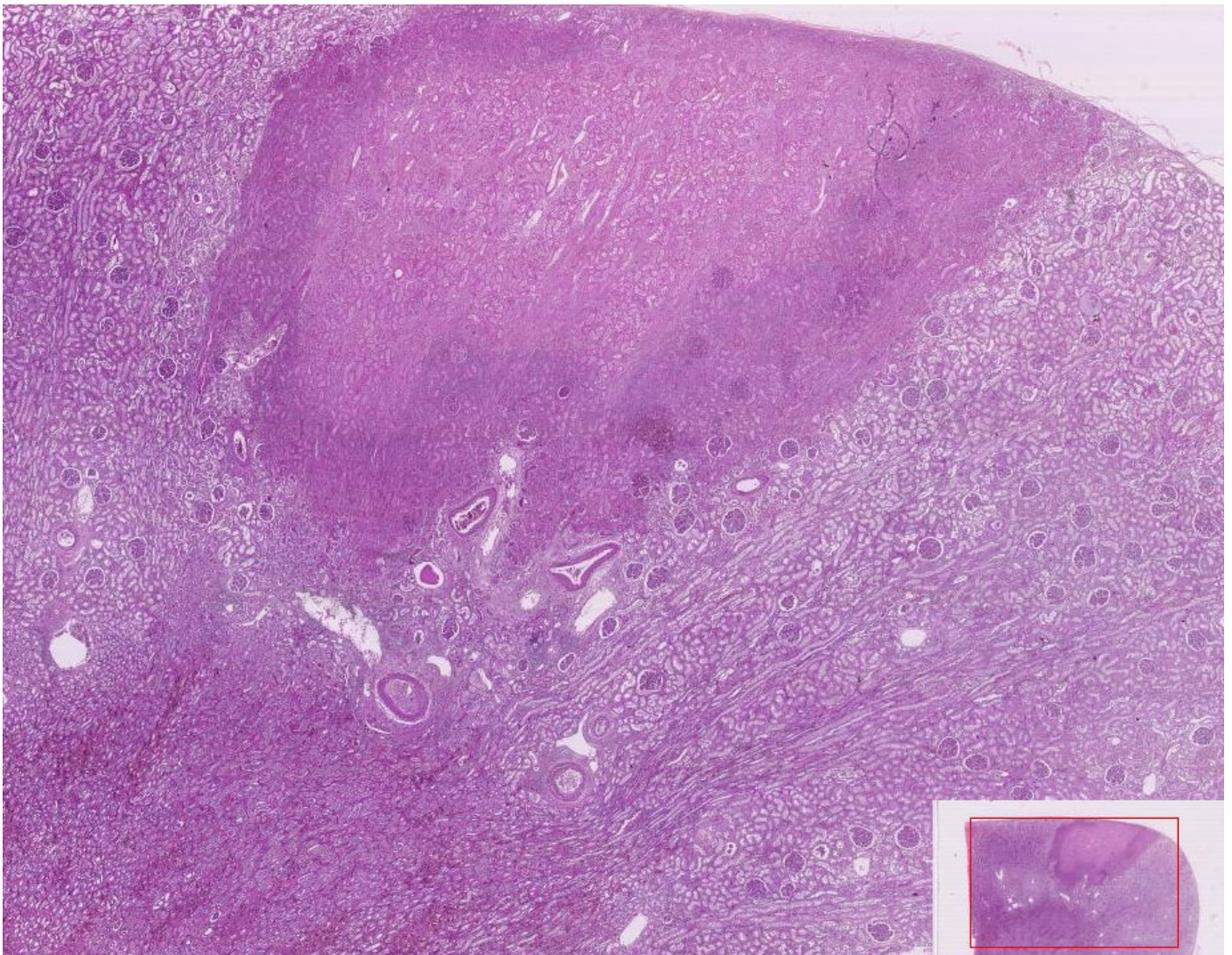


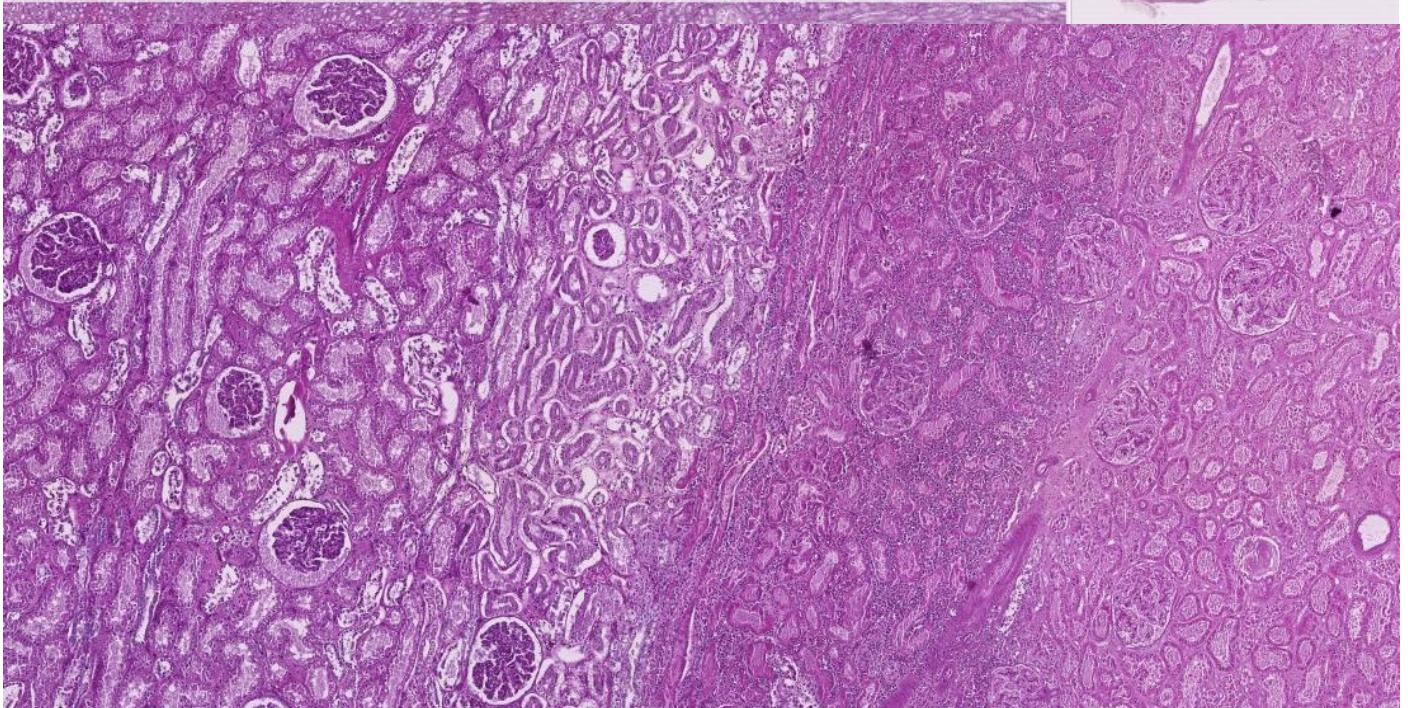
I.1
Fettleber

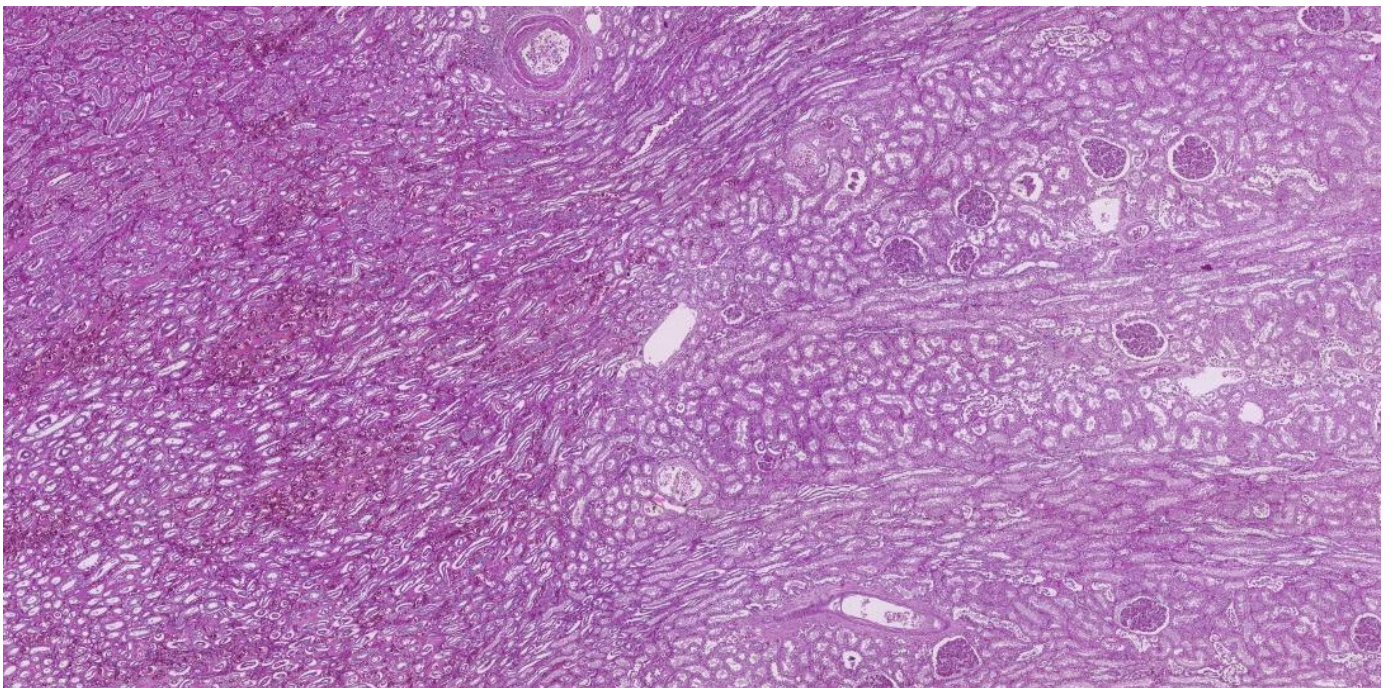
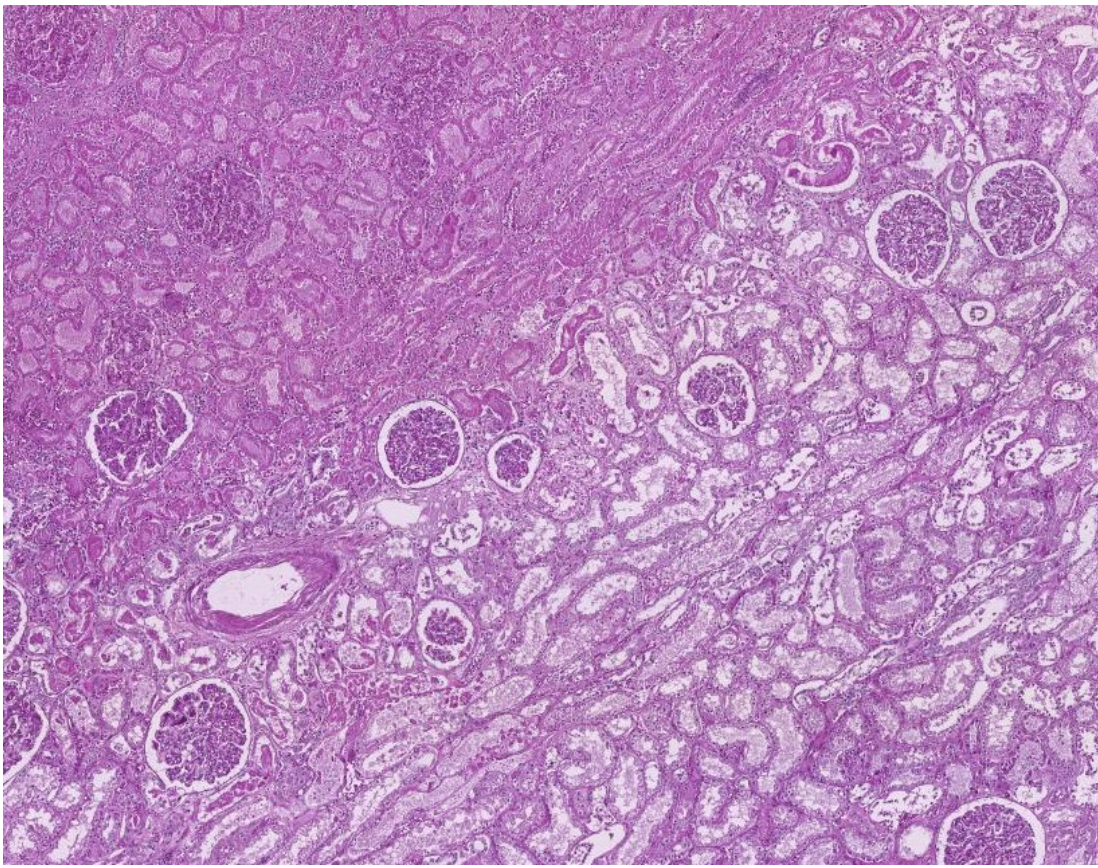


I.2 Anämischer Infarkt der Niere

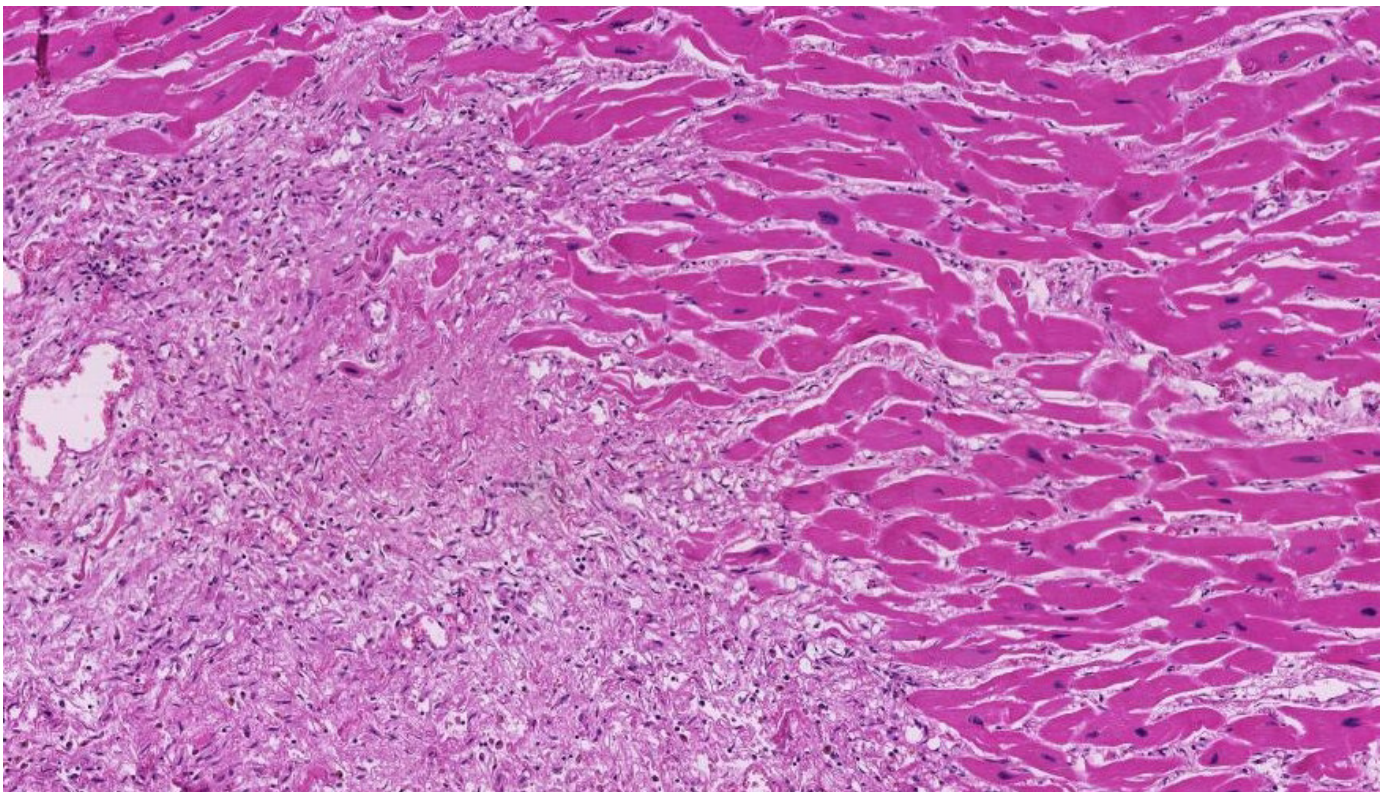
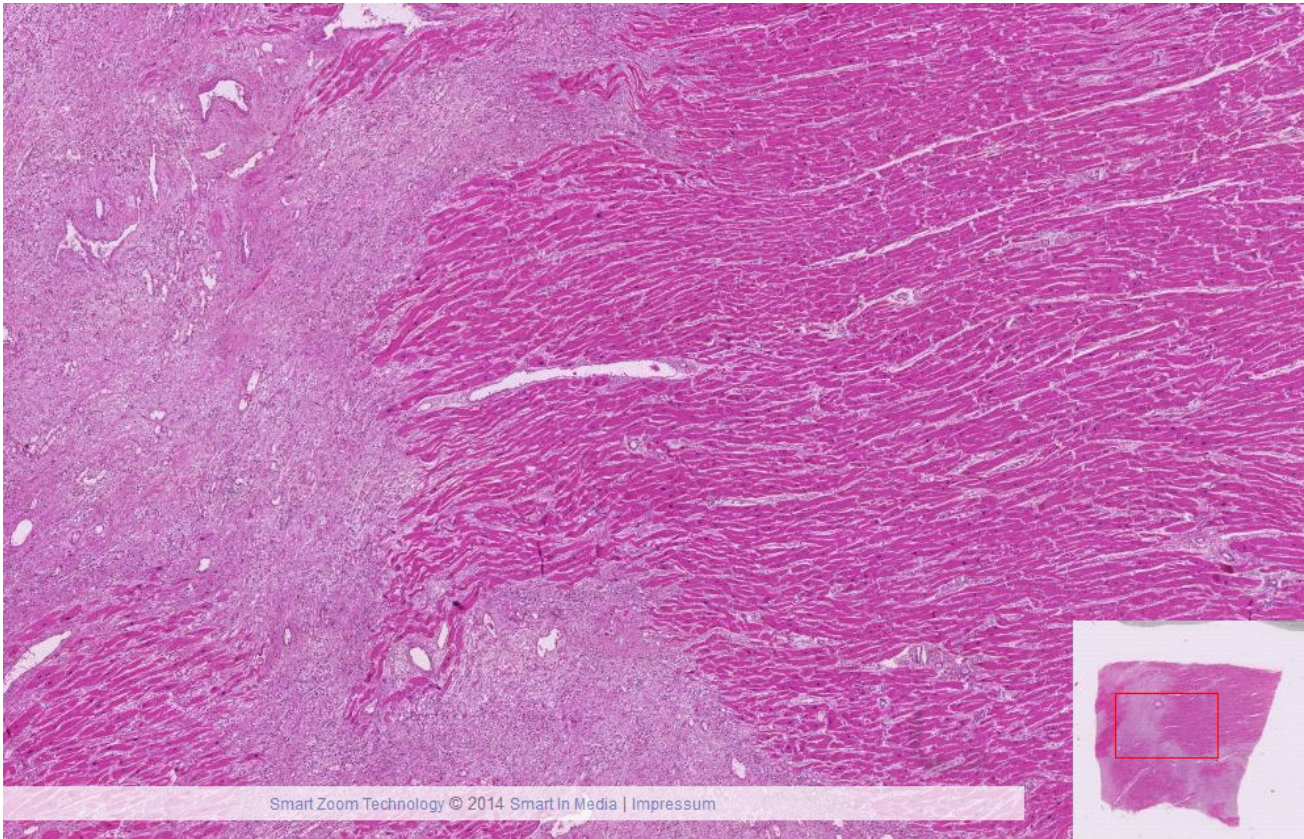


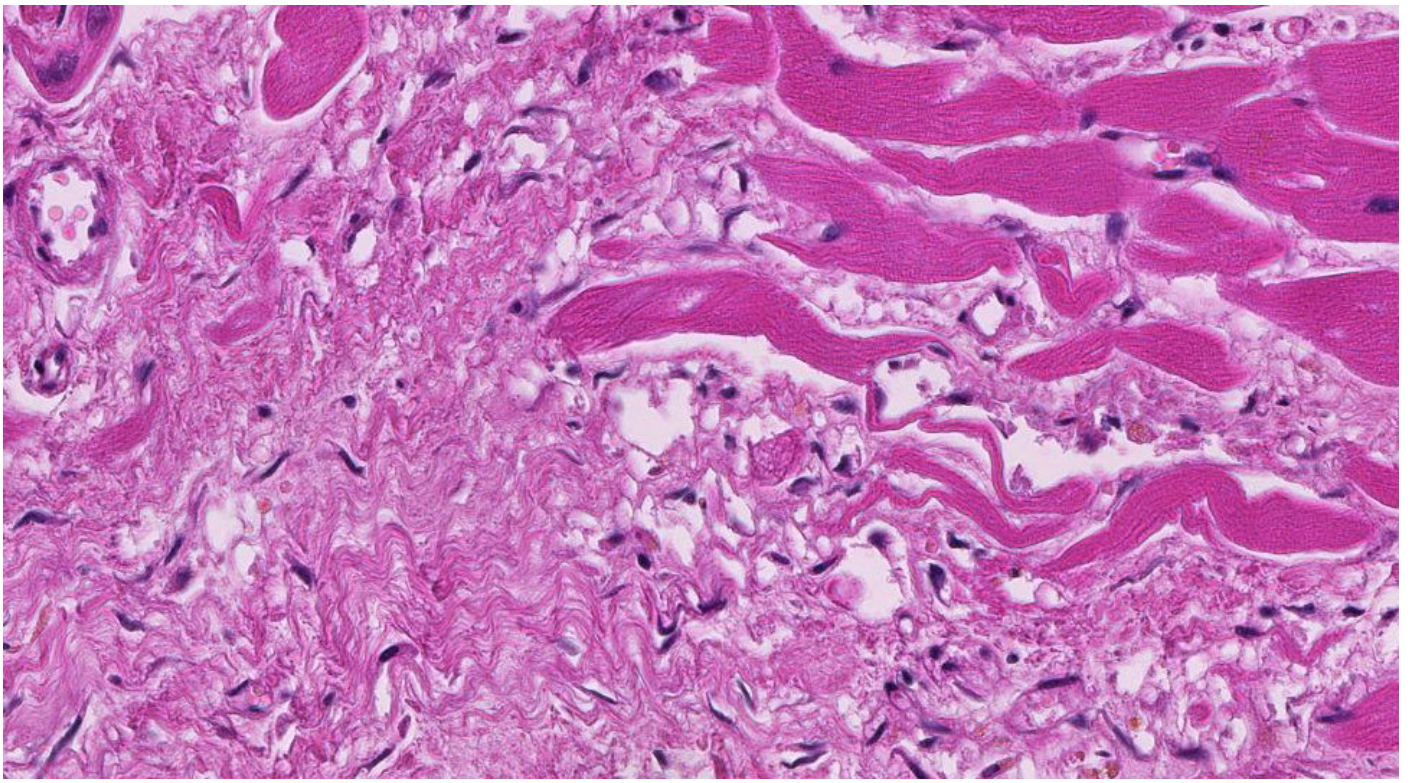
Smart Zoom Technology © 2014 Smart In Media | Impressum



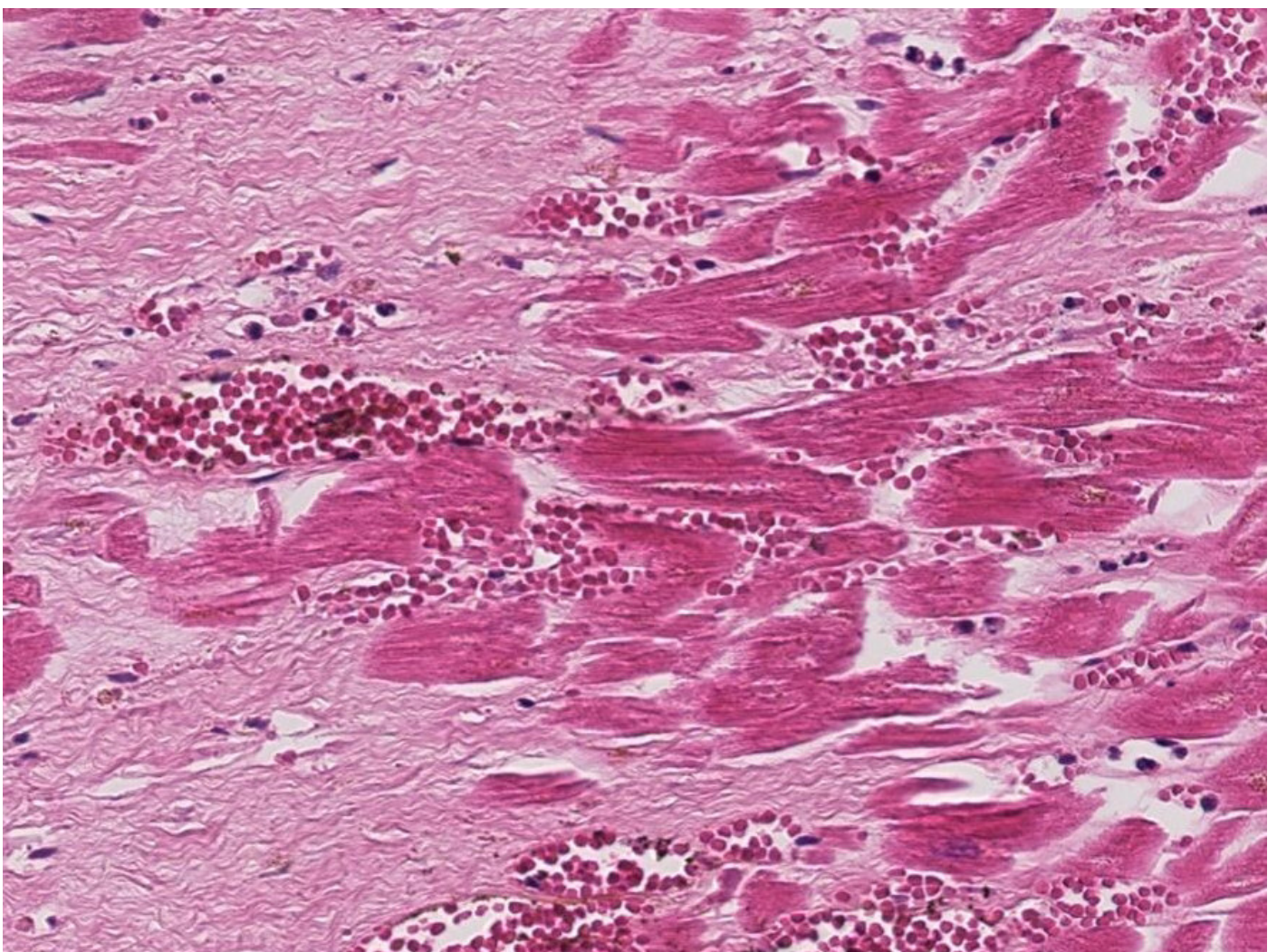
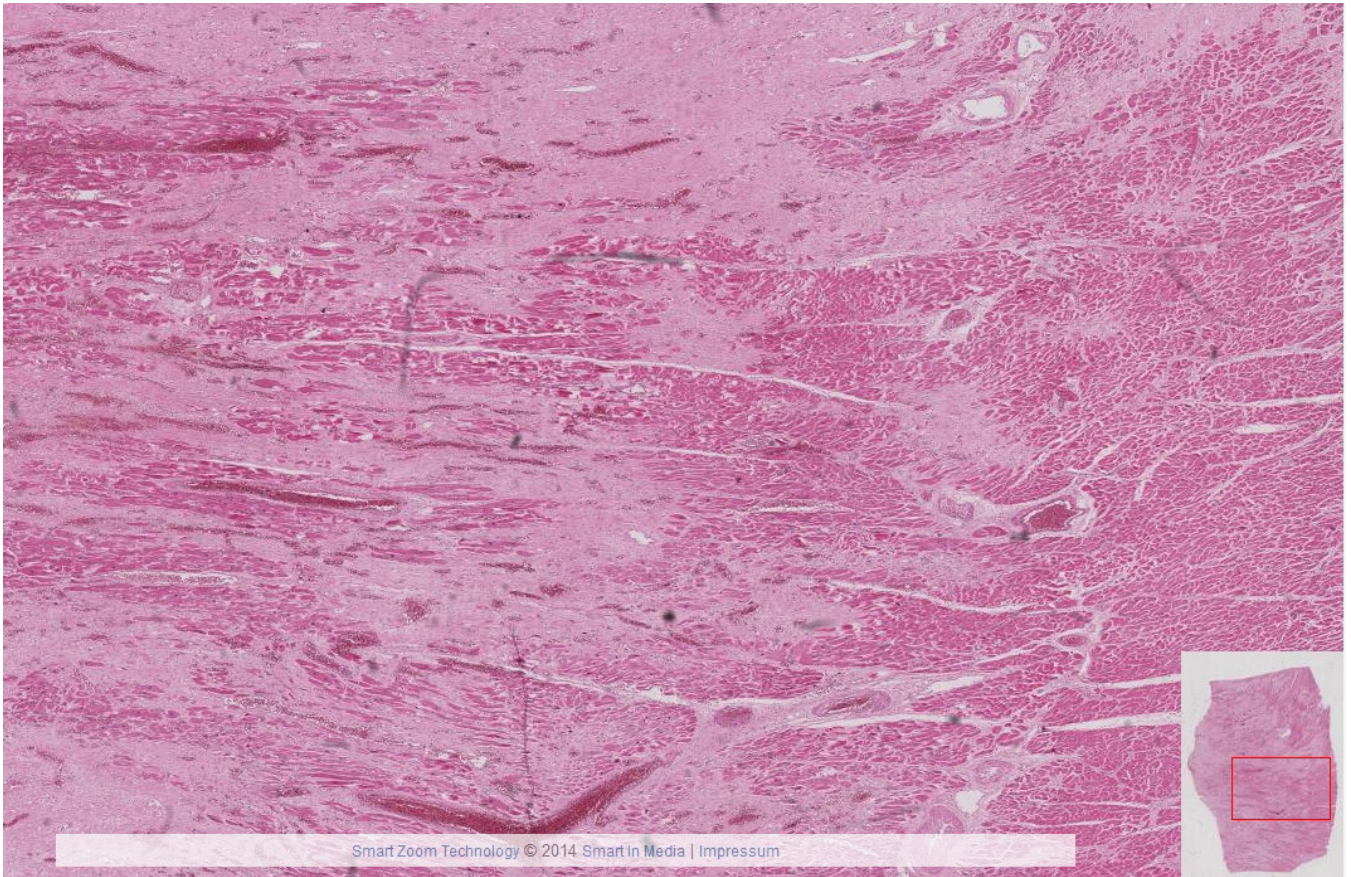


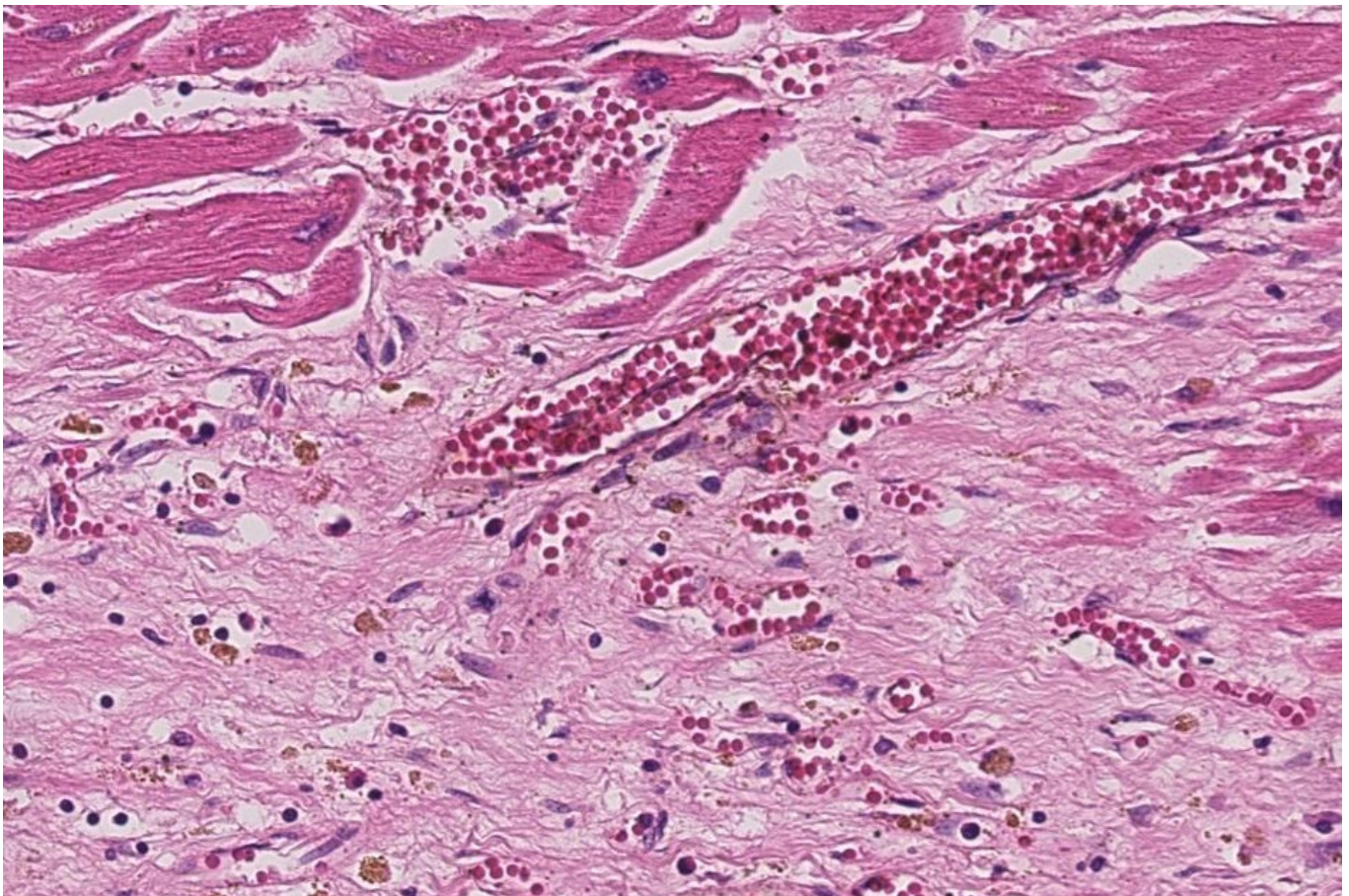
I-3 Herzinfarkt in Organisation



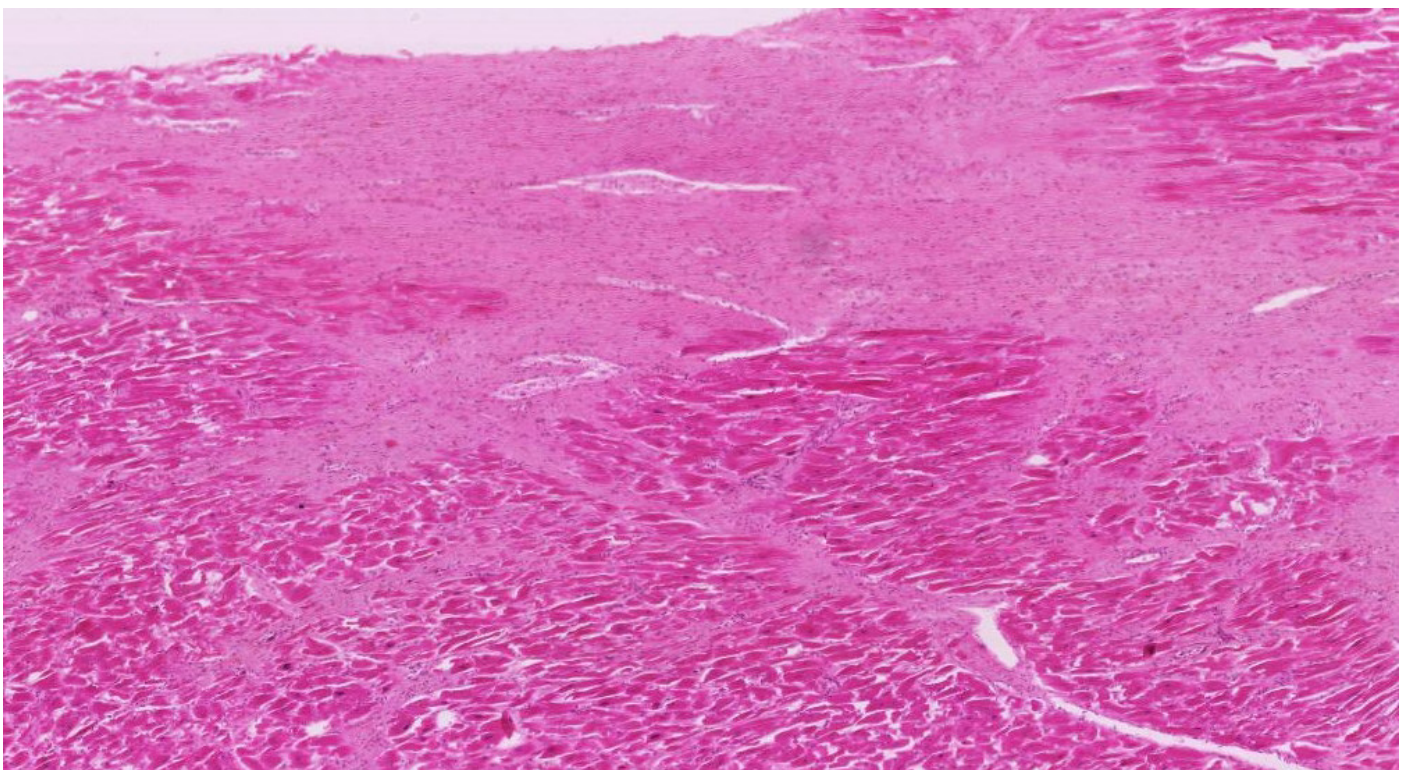


I-4 Herzschiwiele nach Infarkt

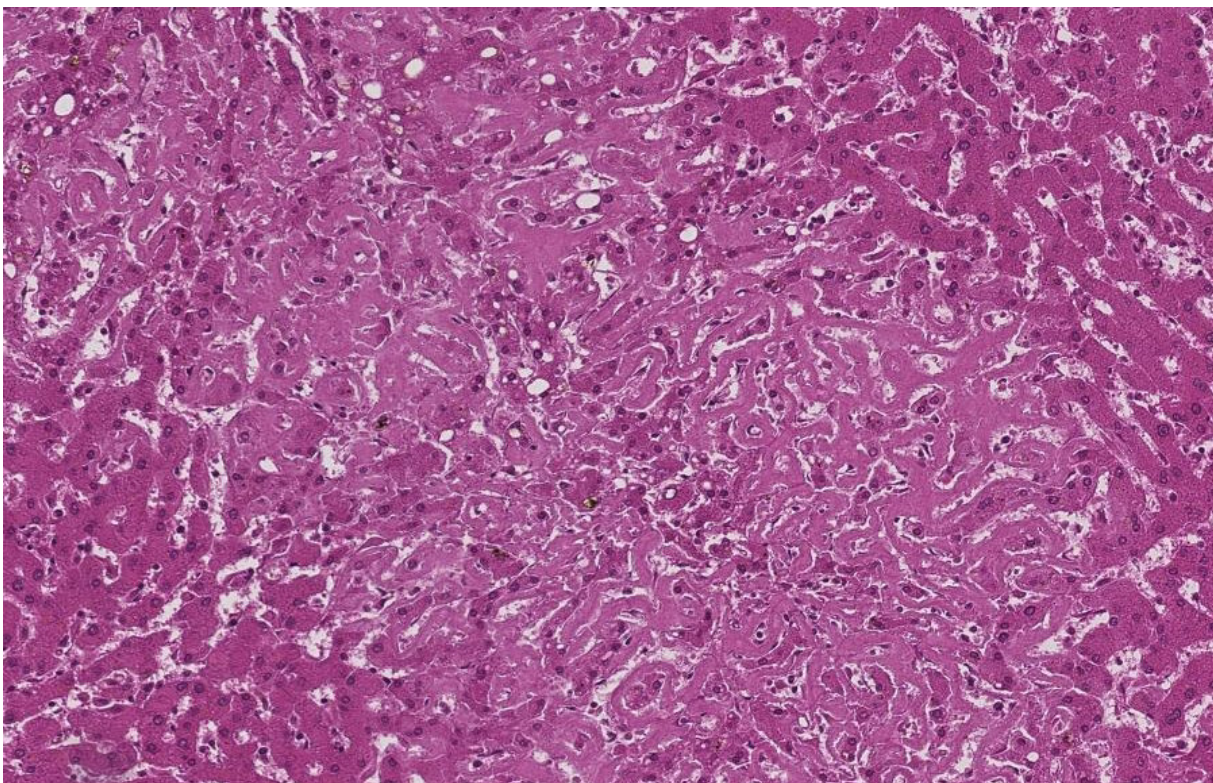
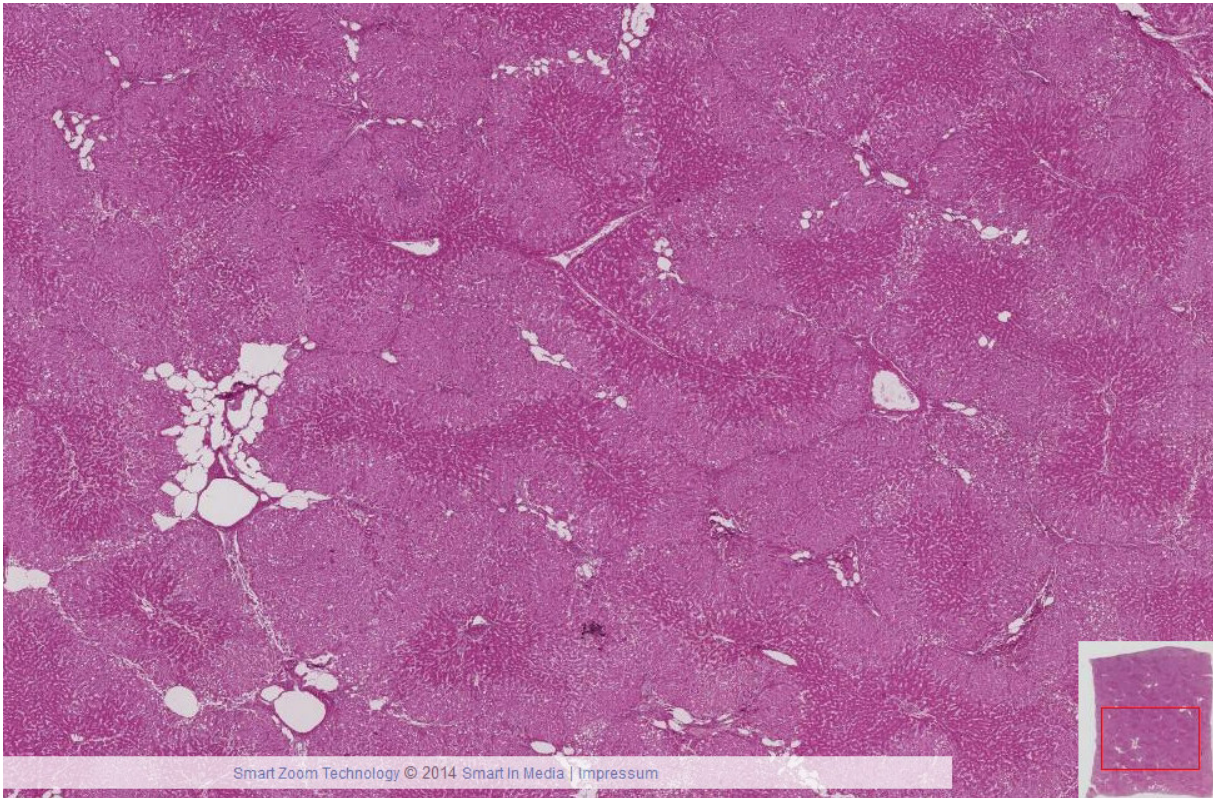


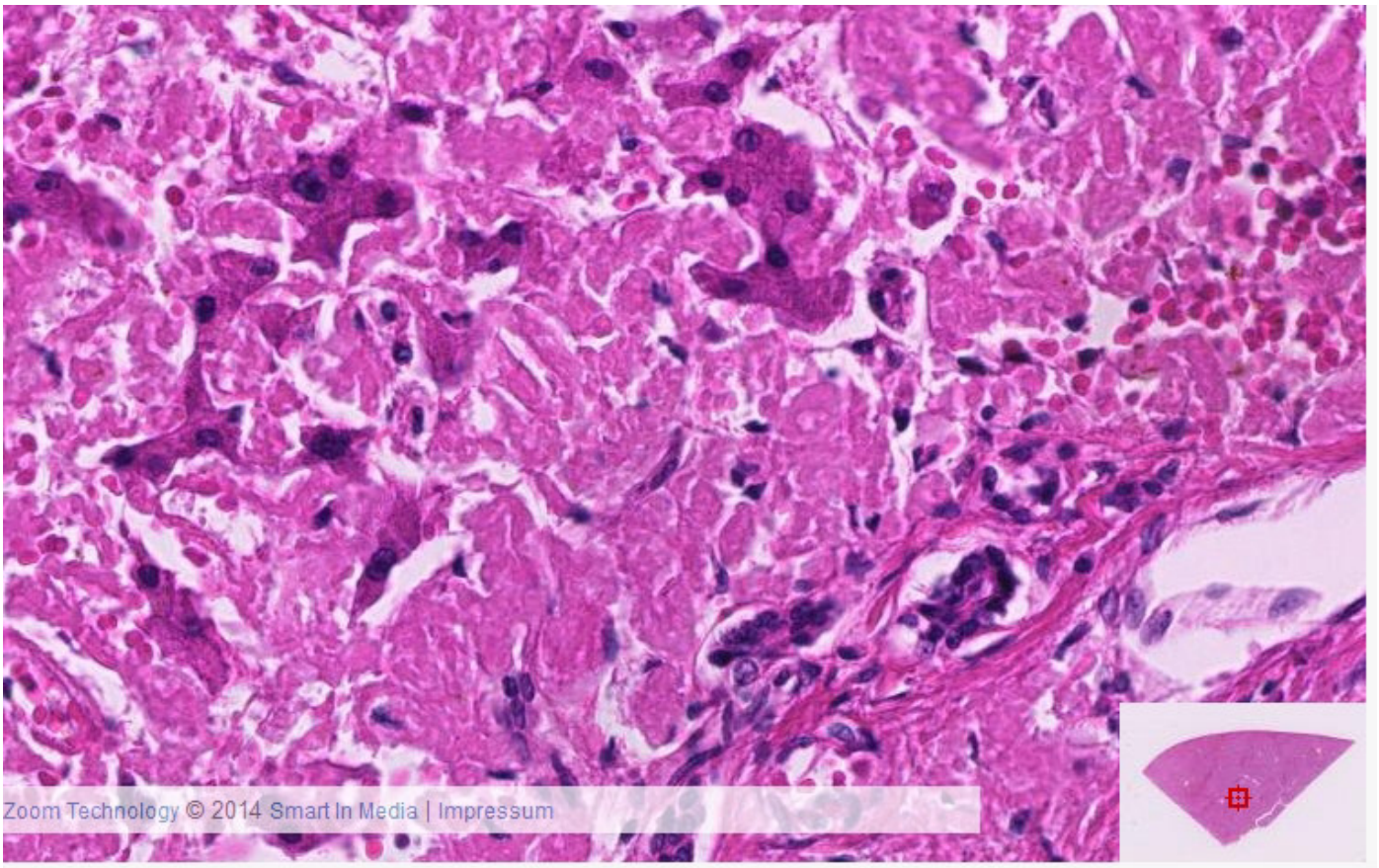


Van Giesonfärbung



I.6 Amyloidose Leber





Zoom Technology © 2014 Smart In Media | Impressum